Students' Corner
Original Article

Contegra valved conduit in the paediatric population: an exciting prospect for right ventricle to pulmonary artery reconstruction; Experience and outcomes at Aga Khan University

Maria Tariq Siddiqui,[1] Asif Hasan,[2] Shazia Mohsin,[3] Mohammad Hamid,[4] Muhammad Muneer Amanullah[5]

Medical Student, Liaquat National Hospital and Medical College, University of Karachi,[1] Department of Congenital Cardiothoracic Surgery, Freeman Hospital, Newcastle Upon Tyne, UK,[2] Department of Paediatric Cardiology,[3] Department of Congenital Cardiac Anaesthesia,[4] Department of Cardiothoracic Surgery,[5] Aga Khan University, Karachi.

Corresponding Author: Muneer Amanullah. Email: muneer.amanullah@aku.edu

Abstract

Objective: The focus of this study is to share the experience and outcomes of Contegra graft implantation in the paediatric and adult population in Pakistan.

Methods: Between May 2007 and July 2011, 16 patients, underwent implantation of a Contegra valved conduit. All operations were performed through a median sternotomy with cardiopulmonary bypass. Indications included: Pulmonary atresia with ventricular septal defect (n=11), Tetralogy of Fallot with absent Pulmonary Valve (PV) syndrome (n=2), double outlet right ventricle, transposition of great arteries and pulmonary stenosis (n=1), isolated aortic valve disease (n=1) and a pseudo-aneurysm with infective endocarditis (n=1).Conduit sizes varied between 16-22 mm.

Results: The three in hospital deaths were unrelated to the Contegra valved conduit. One patient was lost to follow up. Of the 12 survivors, 10 are currently free from re-operation or complications related to the conduit while one needed distal pulmonary artery dilatation owing to critical stenosis and another had severe Valvular regurgitation. Echocardiographic evaluation of the Contegra valved conduit demonstrated no haemodynamically significant valve regurgitation in 10 patients.

Conclusion: In this small review of 16 operations using the Contegra valved conduit for Right Venticular Outflow Tract (RVOT) reconstruction in the paediatric population, we observed good post operative results concerning conduit function. The Contegra conduit provides an excellent substitute to the homograft with satisfactory early and mid-term results though long term results are awaited in Pakistan.

Keywords: Contegra conduit, Right ventricle to pulmonary artery reconstruction, Echocardiography. (JPMA 62: 1113; 2012).

Introduction

The unavailability of homografts has led to a rising demand for conduits for right ventricular outflow tract (RVOT) reconstruction surgery. Xenografts and synthetic grafts have been far from ideal, with increasing long term complications prompting the search for alternatives. One such option is the Contegra (Medtronic Inc., Minneapolis, MN), a biological valved conduit consisting of a heterologous bovine jugular vein with a tri-leaflet valve preserved in glutaraldehyde. Introduced in 1999, it has emerged as a strong contender in RVOT reconstruction surgery. Various studies have been conducted on the clinical outcomes of the conduit in both paediatric and adult population, yielding favourable results.[1,2]

The aim of this study is to share the surgical experience and results of implanting the Contegra valved conduit at the Aga Khan University Hospital, Karachi, Pakistan.

Materials and Methods

This is a retrospective study of an operative technique conducted at the Aga Khan University Hospital from May 2007- July 2011. The data was gathered from March - June 2011. Demographic variables included age, sex distribution, weight, diagnosis, operative techniques, complications and post-operative echocardiographic analysis and length of follow-up. Data was analyzed using the SPSS for Windows (version 17.0) and is expressed as median and minimum and maximum ranges where appropriate. No statistical tests were applied to the data.

All operations were performed via a median sternotomy. The initial dissection to free the pulmonary

arteries and its branches was done prior to establishing cardiopulmonary bypass (CBP). If there were major aorto-pulmonary collateral arteries (MAPCA's) they were also initially dissected free to be ligated or implanted later while on CPB. Cardiopulmonary bypass was established with aortic and bi-caval cannulation and moderate hypothermia of 28°C.

Aortic cross-clamping was applied and myocardial preservation was maintained with intermittent antegrade cold blood cardioplegia for intra-cardiac repair. The VSD was closed with a patch of Dacron usually through a right atriotomy and through the tricuspid valve along with the right ventriculotomy where the proximal end of the Contegra grafts anastomosis was to be fashioned. The Contegra graft was then trimmed to size, with the valve positioned as close to the distal anastomosis as possible. The lie of the Contegra was to the left so that it did not come to lie directly under the sternum. The pulmonary artery was then transected and proximal end transfixed if required.

The pulmonary arteriotomy was extended onto the branch pulmonary artery (PA) with extension into the left pulmonary artery (LPA). This defect was then closed with a patch of Contegra to increase the size of the PA and also to provide a tension free anastomosis away from the delicate pulmonary artery wall. The distal anastomosis between the Contegra and patch on the PA was fashioned with Prolene 5-0 or 4-0 depending on the size of the patient. It was made sure that there was intimal contact but avoided full thickness bites of the Contegra and its patch as the external wall is thick and rough which may later lead to later stenosis. The proximal end was then anastomosed to the right ventricle (RV) in a way that a hood is created. If there was a lack of a hood, a patch of bovine or gluteraldehyde treated autologous pericardium was utilized (Figure). The atriotomy was closed during re-warming. A PFO was always left behind to vent the RV and maintain cardiac output in the setting of post-operative RV dysfunction.

Post-operative echocardiography was performed in all patients at time of discharge, measuring maximum instantaneous gradient across the Contegra and right ventricular ejection fraction (EF) which was measured by visual estimation and Simpson's method. Follow up data was obtained in June 2011, and echocardiography was performed and maximum instantaneous gradient across the Contegra were compared to the results at the time of discharge.

Results

A total of 16 patients (8 males, 8 females) underwent Contegra valved conduit implantation at the Aga Khan University Hospital during the period of May 2007-July 2011. Median age at surgery was 6.6 years (range 1.08-18.00 years), and median weight was 15.5 kg (range 9.1-45.0 kg). A 22mm conduit was implanted in 7 patients, a 20 mm conduit in 6 patients, an 18mm in 2 patients and a 16mm conduit in 1 patient.

Indications included pulmonary atresia with ventricular septal defect (VSD) in 11 patients, Tetralogy of Fallot (ToF) with absent pulmonary valve syndrome (APVS) in 2 patients, double outlet right ventricle (DORV), transposition of great arteries (TGA) and pulmonary stenosis in 1 patient each, an infected pseudo-aneurysm in 1 patient and aortic valve disease needing a Ross procedure in 1 patient.

The patient presenting with a pseudo-aneurysm had undergone a Rastelli procedure abroad. Patients with pulmonary atresia with VSD had also undergone operative

Table-1: Indications and operative procedures.

Group	Patients (n=16)	Etiology	Previous surgery	Operative Procedure
Primary operation				
I	2	Tetralogy of Fallot with absent pulmonary valve syndrome	-	Correction of Fallot's Tetralogy
Second operation				
II	11	All patients had pulmonary atresia and ventricular septal defect with MAPCAS 1 PDA, PFO 1 Hypoplastic conduit	6 patients had undergone a Blalock-Taussig shunts+ and 1 a Rastelli procedure	Rastelli procedure and closure of interventricular communications
III	1	Isolated aortic valve disease	Closure of interventricular communications+ Atrioventricular repair	Ross procedure
IV	1	Pseudoaneurysm of RV to PA conduit with infective endocarditis	Rastelli procedure	Replacement of conduit
V	1	DORV, d-TGA, PS	PA-Band, Rastelli DORV, RV-PA conduit	Complete repair

MAPCAS= major aorto-pulmonary collateral arteries, PDA= patent ductus arteriosus, PFO= patent foramen ovale, TGA= transposition of great arteries, VSD= ventricular septal defect, DORV= Double outlet right ventricle, RV= right ventricle, PA= pulmonary artery.

Table-2:

Serial no	Diagnosis	Size of conduit	Age at surgery	Follow up (months)	Conduit regurgitation	Conduit stenosis (degree)	Conduit aneurysm	Branch PA stenosis
1	PA-VSD	18	5.33	50	moderate	moderate	none	none
2	PA-VSD	18	5.42	25	none	severe	none	severe
3	DORV, D-TGA, PS	20	3.17	19	none	none	none	none
4	PA-VSD	20	3.33	12	severe	none	none	severe
5	ToF-APVS	20	5	50	none	none	none	none
6	PA-VSD	20	5.58	13	none	none	none	none
7	PA-VSD	20	11	1	none	none	none	none
8	PA-VSD	22	6.25	39	none	none	none	none
9	PA-VSD	22	10	44	none	none	none	none
10	PA-VSD	22	11	5	none	none	none	none
11	Aortic Regurgitation	22	11.83	11	none	none	none	none
12	TGA, DORV, PA-VSD, infective endocarditis	22	16	26	moderate	moderate	none	none

PA; pulmonary atresia, VSD; ventricular septal defect, DORV; double outlet right ventricle, TGA; transposition of great arteries, APVS; absent pulmonary valve syndrome.

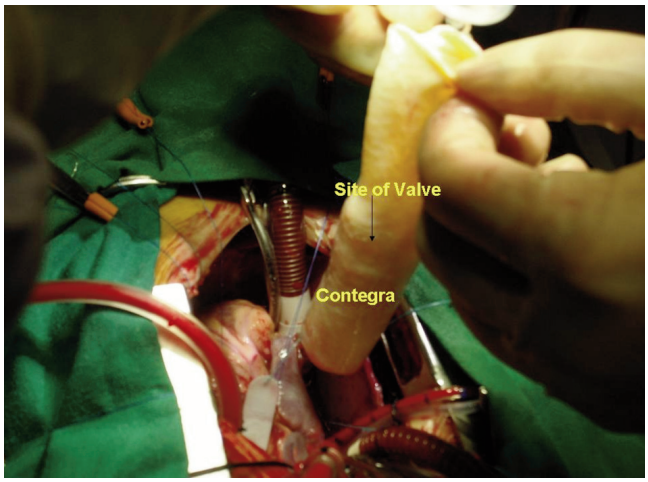

Figure: The Contegra valved conduit about to be used as a right ventricle to pulmonary artery conduit.

interventions, usually a Blalock Taussig shunt insertion. Indications together with previous surgeries are presented in Table-1.

The median by pass time was 207.5 minutes (range 140-390 minutes) and cross clamp time was 135 minutes (range 0-215 minutes).

All patients underwent a trans-thoracic echocardiography measuring maximum instantaneous gradient across the Contegra of 25mmHg (range 10-40mmHg) and a right ventricular ejection fraction of 57.5% (35-65%). There were no immediate post operative morbidities and no patient demonstrated any significant valvular insufficiency. The three early deaths were secondary to pulmonary haemorrhage, cardiogenic shock and plastic bronchitis in the three patients and were hence unrelated to conduit implantation. All remaining patients experienced no conduit related early morbidity, and were free from any reoperations.

A median midterm follow up corresponded to 22 months (range 1-50 months). One patient was lost to follow up corresponding to a midterm follow up rate of 92%. At a 22 month follow-up echocardiographic analysis showed 1 patient having severe pulmonary stenosis and 1 had severe pulmonary regurgitation while 2 had moderate pulmonary stenosis and regurgitation. There was one re-intervention (8%) with dilatation of the LPA secondary to stenosis which was away from the distal conduit anastomosis. There was no replacement required (Table-2).

Discussion

Right ventricle to pulmonary artery conduits have made it possible to palliate congenital heart anomalies including severe Tetralogy of Fallot, truncus arteriosus (TA), pulmonary atresia with or without ventricular septal defect (VSD) and transposition of great arteries with VSD and pulmonary stenosis. First pioneered by Ross et al in 1966,[3] the use of a valved homograft conduit for RVOT reconstruction revolutionized the treatment of right sided congenital cardiac diseases. This initial success led to the use of conduits for the correction of TA in 1968,[4] and for transposition with VSD and pulmonary stenosis in 1969.[5] And since then, with extensive evolvement and refinement of congenital cardiac procedures requiring RVOT reconstruction, the use and demand for conduits especially in the paediatric population, has increased exponentially.

However, the choice of conduit for RVOT reconstruction continues to be a challenge. This is because of the various alternatives available[3] which include stented bovine or porcine xenografts in pericardial tubes, glutaraldehyde fixed aortic or pulmonary roots, non valved tissue or prosthetic conduits, bioprostheses in Dacron tubes and aortic and pulmonary homografts. Amongst all of these, the debate for the search of an ideal conduit is yet to be

settled. The ideal conduit is such that it should be easily implanted, lack degeneration or the development of obstruction, allow for growth, be free from insufficiency and would not require long-term anticoagulation. Cryopreserved pulmonary and aortic homografts have been considered the "gold-standard" since the 1980's.[6] They are non-reactive, have a superior durability, are haemodynamically superior to all other valve prosthetics and do not necessitate life time anti coagulant therapy. Amongst the two, pulmonary homografts are preferred because of their decreased propensity towards obstruction and calcification.[6,7]

The credibility of pulmonary homografts is marred by their diminished supply and restriction in the conduit sizes (10-18 mm). In addition, early and mid term follow up results reveal they undergo shrinkage which predisposes to conduit stenosis and valvular insufficiency. Calcification of conduit also remains a significant problem.[8-11] A prosthetic material is also necessary on the proximal end to provide an aid in creating a hood and connection to the right ventricle. The aforementioned drawbacks led to the search for an alternate conduit for RVOT reconstruction for the Ross procedure and congenital heart defects. The Contegra bovine conduit, introduced in 1999, is one such option. Early animal studies reported encouraging results with excellent haemodynamics, satisfactory valvular function, and absence of any structural degeneration or valve regurgitation at three years interval.[12] Human clinical trials that followed.[13] reaffirmed the claims making Contegra a front runner in the alternative to homograft conduits.

Subsequently reported experience and outcomes of Contegra conduit in congenital surgeries and Ross procedure are increasingly favourable as demonstrated by various clinical results.[14-16] Principal advantages of the Contegra include a large variety of available sizes (12 to 22 mm internal diameter), 'off the shelf' availability, good haemodynamics, unique tailoring options and a moderate cost. Sufficient length is made available at both inflow and outflow tract to facilitate various reconstructive surgical procedures. Taken from the venous circulation, the conduit exhibits the same characteristics of a low pressure circulation as required for the pulmonary vascular tree. Some reports claim the haemodynamic performance of the Contegra in the Ross procedure to be better than that of the homografts.[17,18] The reported complications with Contegra have been critical dilatation, insufficiency, calcification, and repeated stenosis in the pulmonary artery region.[19-21] The last has been a significant factor in conduit related failure.

This study describes our surgical experience of the implantation of the Contegra valved conduit in 16 patients. In our study, with a limited follow up of 22 months 10 conduits remained free from any complication. There was one re-intervention in our series owing to critical stenosis of the left pulmonary artery just distal to the anastomosis requiring balloon dilatation. Another patient has severe pulmonary regurgitation secondary to bilateral distal branch pulmonary artery stenosis away from the distal conduit anastomosis. The remaining patients have been of any findings suggestive of conduit failure due to obstruction, dilatation and calcification or are in NYHA class I. Brown et al using a similar technique reported a branch PA stenosis of 1.5%; another study reported six reoperations in 108 Contegra implantations due to distal pulmonary artery stenosis.[21,22] We determined that the pulmonary artery should be patched and the Contegra should be anastomosed to the patch rather than the artery itself. This helps in avoiding the contact of direct sheer forces on the delicate pulmonary artery. We also believe avoiding full thickness of the Contegra in the lumen, as it leads to the development of a neo-intimal peel at the anastomosed area and maybe a major cause of conduit obstruction. In accordance, Brown et al reaffirms this with a plausible explanation suggesting that the inclusion of a conduit into the lumen results in deposition of platelets and white blood cells that prompts the consequent stenosis at the distal conduit anastomosis. This occurs because the xenogenic tissue retains residual antigenticity where both class I and II major histocomaptibilty complex (MHC) residual antigens can remain active.[22]

Various authors also believe that suture technique is an important factor in preventing stenosis, with one suggesting the use of a continuous suture with every third stitch locked posteriorly and an interrupted suture anteriorly.[22] Also distal conduit anastomosis is advised to be towards the left pulmonary artery as it prevents contact between the lesser curvature of the ascending aorta and distal Contegra anastomosis, which may potentially induce conduit narrowing.[1,23] The valve should also be kept as distal as possible from the RV anastomosis. We advise that the hood be kept reasonably wide, but avoid a balloon hood as it leads to loss of energy of the ejected blood.

Conclusion

In conclusion, the Contegra is a promising easily available substitute to the pulmonary homograft. The early and intermediate results obtained at our institution are in accordance with results found at other institutions where the conduit has been deployed. However further studies need to be carried out to determine long-term results in Pakistan.

References

1. Breymann T, Blanz U, Wojtalik MA, Daenen W, Hetzer R, Sarris G, et al. European Contegra multicentre study: 7-year results after 165 valved bovine jugular vein graft implantations. Thorac Cardiovasc Surg 2009; 57: 257-69.

2. Niclauss L, Delay D, Hurni M, von Segesser LK. Experience and intermediate-term results using the Contegra heterograft for right ventricular outflow reconstruction in adults. Interact Cardiovasc Thorac Surg 2009; 9: 667-71.

3. Ross DN, Somerville J. Correction of pulmonary atresia with a homograft aortic valve. Lancet 1966; 2: 1446-7.

4. McGoon DC, Rastelli GC, Ongley PA. An operation for the correction of truncus arteriosus. JAMA 1968; 205: 69-73.

5. Rastelli GC, Wallace RB, Ongley PA. Complete repair of transposition of the great arteries with pulmonary stenosis: a review and report of a case corrected by using a new surgical technique. Circulation 1969; 39: 83-95.

6. Bando K, Danielson GK, Schaff HV, Mair DD, Julsrud PR, Puga F. Outcome of pulmonary and aortic homografts for right ventricular outflow tract reconstruction. J Thorac Cardiovasc Surg 1995; 109: 509-18.

7. Perron J, Moran AM, Gauvreau K, del Nido PJ, Mayer JE Jr, Jonas RA. Valved homograft conduit repair of the right heart in early infancy Ann Thoracic Surg 1999; 68: 542-8.

8. Brown JW, Ruzmetov M, Rodefeld MD, Vijay P, Turrentine MW. Right ventricular outflow tract reconstruction with an allograft conduit in non-ross patients: risk factors for allograft dysfunction and failure. Ann Thorac Surg 2005; 80: 655-63.

9. Christenson JT, Sierra J, Colina Manzano NE, Jolou J, Beghetti M, Kalangos A Homografts and xenografts for right ventricular outflow tract reconstruction: long-term results. Ann Thorac Surg 2010; 90: 1287-93.

10. Brown JW, Ruzmetov M, Rodefeld MD, Vijay P, Turrentine MW. Right ventricular outflow tract reconstruction with an allograft conduit in non-ross patients: risk factors for allograft dysfunction and failure. Ann Thorac Surg 2005; 80: 655-63.

11. Gerestein CG, Takkenberg JJ, Oei FB, Cromme-Dijkhuis AH, Spitaels SE, van Herwerden LA et al. Right ventricular outflow tract reconstruction with an allograft conduit. Ann Thorac Surg 2001; 71: 911-7.

12. Ichikawa Y, Noishiki Y, Kosuge T, Yamamoto K, Kondo J, Matsumoto A. Use of a bovine jugular vein graft with natural valve for right ventricular outflow tract reconstruction: a one-year animal study. J Thorac Cardiovasc Surg 1997; 114: 224-33.

13. Breymann T, Thies WR, Boethig D, Goerg R, Blanz U, Koerfer R. Bovine valved venous xenografts for RVOT reconstruction: results after 71 implantations. Eur J Cardiothorac Surg 2002; 21: 703-10.

14. Sfyridis PG, Avramidis DP, Kirvassilis GV, Zavaropoulos PN, Papagiannis JK, Sarris GE.The contegra® valved heterograft conduit for right ventricular outflow tract reconstruction: a reliable solution. Hellenic J Cardiol 2011; 5: 501-8.

15. Palma G, Mannacio VA, Mastrogiovanni G, Russolillo V, Cioffi S, Mucerino M, Vosa C. Bovine valved venous xenograft in pulmonary position: medium term evaluation of risk factors for dysfunction and failure after 156 implants. J Cardiovasc Surg 2011; 52: 285-91.

16. Purohit M, Kitchiner D, Pozzi M. Contegra bovine jugular vein right ventricle to pulmonary artery conduit in Ross procedure. Ann Thorac Surg 2004; 77: 1707-10.

17. Corno AF, Hurni M, Griffin H, Jeanrenaud X, von Segesser LK. Gluteraldehyde fixed bovine jugular veun as a substitute for pulmonary valve in the Ross operation. J Thoracic Cardiovasc Surg 2001; 122: 493-4.

18. Corno AF, Hurni M, Griffin H, Galal OM, Payot M, Sekarski N et al. Bovine jugular vein as right ventricle-to-pulmonary artery valved conduit. J Heart Valve Dis 2002; 11: 242-7.

19. Gist KM, Mitchell MB, Jaggers J, Campbell DN, Yu JA, Landeck BF 2nd Assessment of the relationship between contegra conduit size and early valvularar insufficiency. Ann Thorac Surg 2012; 93: 856-61.

20. Morales DL, Braud BE, Gunter KS, Carberry KE, Arrington KA, Heinle JS et al Encouraging results for the Contegra conduit in the problematic right ventricle-to-pulmonary artery connection. J Thorac Cardiovasc Surg 2006; 132: 665-71.

21. Boethig D, Thies WR, Hecker H, Breymann T. Mid term course after pediatric right ventricular outflow tract reconstruction: a comparison of homografts, porcine xenografts and Contegras. Eur J Cardiothorac Surg 2005; 27: 58-66.

22. Brown JW, Ruzmetov M, Rodefeld MD, Vijay P, Darragh RK. Valved bovine jugular vein conduits for right ventricular outflow tract reconstruction in children: an attractive alternative to pulmonary homograft. Ann Thorac Surg 2006; 82: 909-16.

23. Chatzis AC, Giannopoulos NM, Bobos D, Kirvassilis GB, Rammos S, Sarris GE. New xenograft valved conduit (Contegra) for right ventricular outflow tract reconstruction. Heart Surg Forum 2003; 6: 396-8.